



Case report

Staged bilateral thalamic electrode implantation utilizing frameless stereotactic guidance

Shearwood McClelland III ^a, Patrick B. Senatus ^b, Blair Ford ^c,
 Guy M. McKhann II ^b, Robert R. Goodman ^{b,*}

^a Department of Neurosurgery, University of Minnesota Medical School, Minneapolis, Minnesota, USA

^b Department of Neurological Surgery, Neurological Institute of New York, Columbia College of Physicians and Surgeons, 710 West 168th Street, Box 99, New York, New York, USA

^c Department of Neurology, Neurological Institute of New York, Columbia College of Physicians and Surgeons, New York, New York, USA

Received 24 February 2006; accepted 28 March 2006

Abstract

Deep brain stimulation (DBS) for medically intractable Parkinson's disease (PD) is well established, but carries the inconveniences of frame-based neurosurgery. Previous reports have demonstrated that ventricular shunt placement and some functional procedures can be accurately performed using frameless stereotaxy. We present a report indicating that staged deep brain electrode placement can be accurate and efficacious using a frameless skull-mounted guide.

© 2006 Elsevier Ltd. All rights reserved.

Keywords: Deep brain stimulation; Frameless stereotactic guidance; Staged implantation; Parkinson disease

1. Case illustration

Deep brain stimulation (DBS) for medically intractable Parkinson's disease (PD) is well established, but carries the inconveniences of frame-based neurosurgery.^{1–3} Previous reports have demonstrated that ventricular shunt placement and some functional procedures can be accurately performed using frameless stereotaxy.^{4,5} We present a report indicating that staged deep brain electrode placement can be accurate and efficacious using a frameless skull-mounted guide.

A 69-year-old man with a progressive 13-year history of atypical Parkinson syndrome characterized by severe high-amplitude full-body tremors during 'off' periods that were increasingly refractory to medication was recommended for bilateral thalamic stimulation therapy. Three days before electrode implantation skull fiducials were placed un-

der local anesthesia in an ambulatory setting. Thin-slice T1-weighted spoiled gradient recalled acquisition in steady state (SPGR) volumetric axial images were obtained and transferred to a Stealth FrameLink 4 program (Medtronic Inc., Minneapolis, MN, USA) for surgical planning.

The patient was admitted three days later and had an uncomplicated implantation of a right ventralis intermedius (VIM) thalamic DBS electrode (model 3387; Medtronic Inc.). This was performed using a skull-mounted guide (Navigus Deep Brain Access Tower; Image-Guided Neurologics, Melbourne, FL, USA) with trajectory determined by a frameless stereotactic tool with the Stealth Workstation (Cranial 4; Medtronic Inc.). A modified Philadelphia cervical collar (Philadelphia Collar Co., Philadelphia, PA, USA) was used to stabilize the patient's head. The length of the anterior commissure-posterior commissure (AC/PC) line was 24.75 mm, and the calculated target was 13.6 mm lateral, 6.2 mm posterior, and 0 mm superior to the AC/PC plane. Electrode placement resulted in reduction of tremor, with complete left hand tremor suppression

* Corresponding author. Tel.: +1 212 305 3774; fax: +1 212 305 3629.
 E-mail address: rrg2@columbia.edu (R.R. Goodman).

below 3 V using high-frequency bipolar stimulation. Because there were no adverse effects with this stimulation, the electrode was maintained at the initial target point.

The patient was discharged in a stable condition and one week later had contralateral VIM DBS electrode placement (model 3387) using the same skull fiducials and a non-invasive head ring secured to a Mayfield adaptor (Image-Guided Neurologics). His calculated target was the same as for the right-sided electrode. Because his threshold for right-hand paresthesias was 1 V, and at 3 V he had transient right hand paresthesias without any side-effects, the initial target was used for this side as well.

Because VIM stimulation via the DBS electrodes produced excellent tremor control and the expected sensory responses, only one electrode penetration was used for each

surgery. One week later, device implantation was completed under general anesthesia, consistent with previous reports.^{2,3} Postoperative CT scan (merged with preoperative MRI) confirmed excellent coincidence between planned target and final electrode position for the right (Fig. 1) and left electrodes. Subsequent stimulation therapy produced excellent bilateral tremor control without side-effects. Of the two different head support systems used, the modified Philadelphia cervical collar provided better comfort and support.

Although some centers utilizing frameless guidance prefer to implant both electrodes simultaneously,⁴ it is the preference of the surgeon (RRG) to stage the procedure in order to confirm that there has been no post-implant hemorrhage or other morbidity following the first

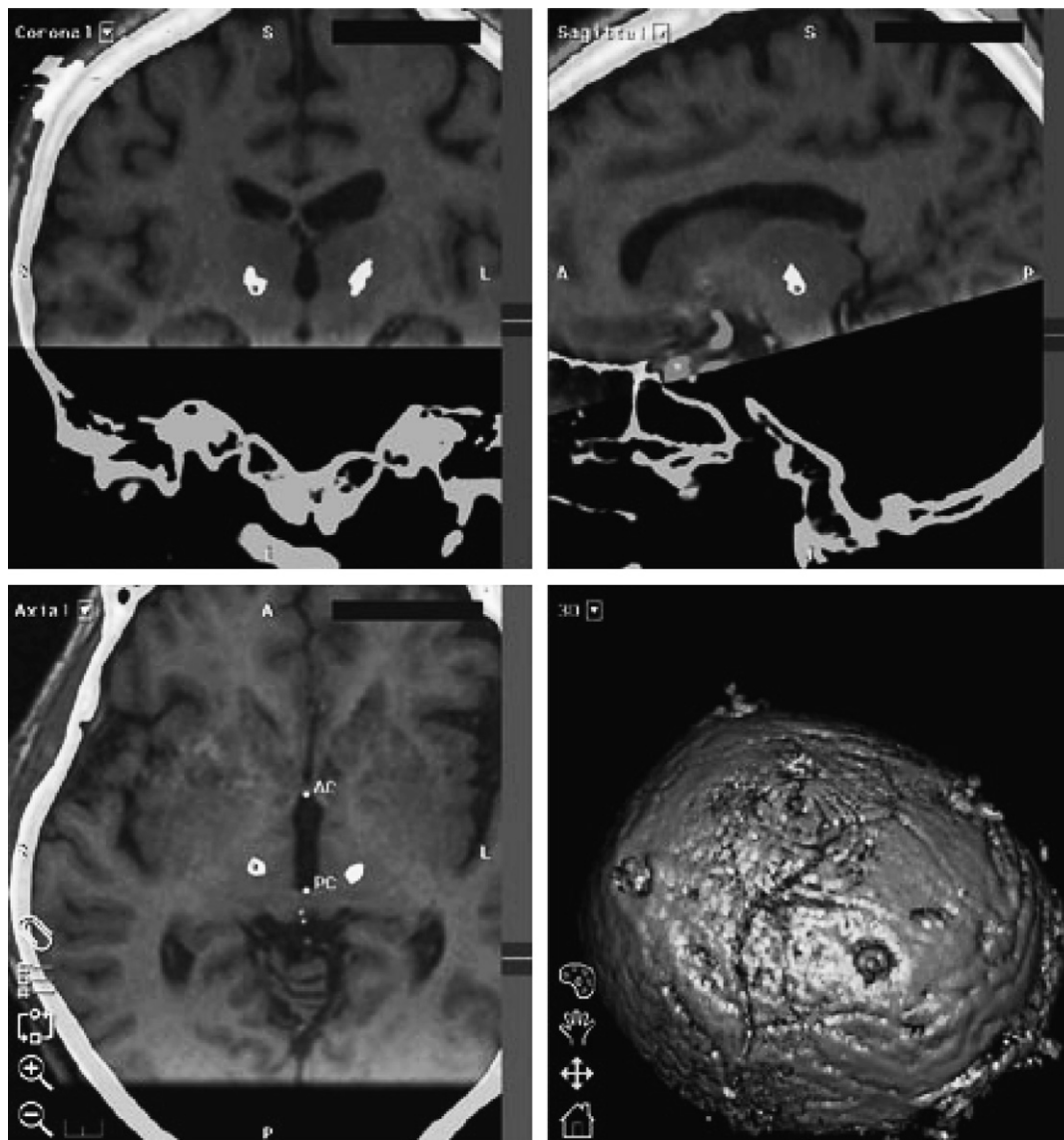


Fig. 1. Postoperative CT merged with preoperative volumetric axial T1-weighted MRI demonstrating coronal, sagittal and axial views of both ventralis intermedius (VIM) deep brain stimulation electrode tips along with the 3D image reconstruction (depicting the skull fiducials) on the Stealth FrameLink 4.0 workstation (Medtronic Inc., Minneapolis, MN, USA). The calculated right-sided target (dark dot) is near the center of the electrode tip artifact (white). Similar results were obtained for the left VIM target (not shown).

implant before proceeding with the contralateral implant. Comparative experience with frame-based electrode implants has shown us that for most patients, placement of skull fiducials has approximately the same degree of discomfort as frame placement. However, a number of patients find the frame application itself to be uncomfortable or painful, while patients having the screw implants have rarely complained of any pain at each of the implant sites. Additionally, the experience of having the head inside the frame during surgery is uncomfortable to many patients, and may induce respiratory obstruction due to fixation of the neck. The freedom of small neck motion allowed with the Philadelphia collar when we used the skull-mounted guide provided greater patient comfort.

Our experience with this patient demonstrates that the skull-mounted guide can be used successfully for DBS implants.⁴ The planned target being well inside the MRI artifact (Fig. 1) indicates that the final electrode tip placement was certainly within 1.5 mm of the intended target, which is comparable to the accuracy that has been documented with frame-based implants.^{2,3}

In conclusion, we present an experience with staged DBS utilizing frameless stereotactic guidance. Staged electrode placement using a frameless skull-mounted guide was accurate, efficacious, increased patient comfort, allowed the convenience of advanced preoperative imaging and planning, eliminated the need for a stereotactic frame,

and permitted the use of one reference system for staged procedures.

2. Financial disclosure information

None of the authors received any financial support in conjunction with the generation of this article.

Acknowledgement

We would like to thank Mary Marshall for invaluable assistance.

References

1. Benabid AL, Pollak P, Gross C, et al. Acute and long-term effects of subthalamic nucleus stimulation in Parkinson's disease. *Stereotact Funct Neurosurg* 1994;**62**:76–84.
2. Starr PA, Christine CW, Theodosopoulos PV, et al. Implantation of deep brain stimulators into the subthalamic nucleus: technical approach and magnetic resonance imaging-verified lead locations. *J Neurosurg* 2002;**97**:370–87.
3. McClelland S 3rd, Ford B, Senatus PB, et al. Subthalamic stimulation for Parkinson disease: determination of electrode location necessary for clinical efficacy. *Neurosurg Focus* 2005;**19**:E12.
4. Holloway KL, Gaede SE, Starr PA, et al. Frameless stereotaxy using bone fiducial markers for deep brain stimulation. *J Neurosurg* 2005;**103**:404–13.
5. Woodworth GF, McGirt MJ, Elfert P, et al. Frameless stereotactic ventricular shunt placement for idiopathic intracranial hypertension. *Stereotact Funct Neurosurg* 2005;**83**:12–6.